Cancer Treatment and Research Communications 45 (2025) 100997

Contents lists available at ScienceDirect

Cancer Treatment and Research Communications

journal homepage: www.sciencedirect.com/journal/cancer-treatment-and-research-communications

Review Article

Systemic therapy breakthroughs in the management of brain metastases: A new era for HER2-positive breast cancer

Martina Parenza Arenhardt [a,*], Carolina Martins Vieira [a], Angélica Nogueira-Rodrigues [a,b]

[a] Oncoclínicas&Co – Medica Scientia Innovation Research (MEDSIR), São Paulo 04542-390, Brazil
[b] Department of Internal Medicine at the Federal University of Minas Gerais, Brazil

ARTICLE INFO

Keywords:
Breast cancer
HER2
Brain metastases
Systemic treatment

ABSTRACT

HER2-positive subtype accounts for 15–20 % of metastatic breast cancer (mBC) cases and is associated with a high incidence of brain metastases (BMs), which affects 35–50 % of the patients, contributing to poor outcomes. Although HER2-targeted therapies have significantly improved overall survival (OS), central nervous system (CNS) involvement remains a significant challenge due to the blood-brain barrier (BBB), which limits systemic treatment efficacy. The advent of antibody-drug conjugates (ADCs) has introduced promising therapeutic options with demonstrated CNS activity.

This narrative review synthesizes current evidence on systemic treatments for HER2-positive BMs. A comprehensive literature search included PubMed, ASCO, ESMO, and NCCN guidelines, as well as ongoing trials from ClinicalTrials.gov.

Until recently, the HER2CLIMB regimen—combining tucatinib, trastuzumab, and capecitabine—was the most effective option for CNS disease control, achieving a median CNS progression-free survival (PFS) of 9.9 months. However, recent trials highlight the transformative impact of antibody-drug conjugates (ADCs), particularly trastuzumab deruxtecan (T-DXd), in this clinical setting. Pooled analyses from the DESTINY-Breast trials reported intracranial overall response rates (IC—ORR) of 45.5 % in untreated and 45.2 % in treated BMs. Smaller studies, such as DEBBRA and TUXEDO-1, demonstrated IC—ORRs of 66.7 % and 73.3 %, respectively, with TUXEDO-1 reporting a median PFS of 14 months. The phase III/IV DESTINY-Breast12 trial further validated T-DXd's efficacy in active BMs, achieving a CNS PFS of 17.3 months and an IC—ORR of 62.3 %, with the highest responses (82.6 %) in untreated BMs.

The current analysis reviews the available data on managing brain metastasis and highlights T-DXd's potential to redefine treatment strategies. It also discusses unanswered questions, such as the role of radiotherapy in asymptomatic disease and the evolving landscape of ADCs.

Introduction

Approximately 15–20 % of breast cancers are classified as HER2-positive, defined by HER2 expression detected through immunohistochemistry (IHC) with a score of 3+ or a score of 2+ associated with gene amplification confirmed by fluorescence in situ hybridization (FISH) [1]. The outcomes of HER2-positive metastatic breast cancer (mBC) have been significantly improved with the addition of HER-2 targeted therapies. The CLEOPATRA trial, which combined chemotherapy with dual HER2 blockade, was a groundbreaking study, achieving a median overall survival of over 50 months for the first time [2]. Despite these advances, approximately 35–50 % of patients with HER2-positive mBC will develop brain metastases (BMs) during their disease course, which is associated with a poor prognosis [3]. To evaluate the demand for local control of active BMs, the European Society of Clinical Oncology (ESMO) guideline considers the number of lesions (1, 1–10, >10) and the presence of favorable prognostic factors. The options for local control should also be based on the patient's symptoms and disease volume [4,5]. Local treatment can be applicable in cases of progression within the central nervous system (CNS) when extracranial disease remains stable, and may be administered in these cases while maintaining the same systemic therapy [5,6]. The recommendation for local treatment is based on the efficacy of radiotherapy and the limited effectiveness of systemic drugs in the CNS [3]. Trastuzumab, the first approved targeted

* Corresponding author at: Belo Horizonte, Minas Gerais, Roma Street, 561 Santa Lucia, Brazil.
E-mail address: tinaparenza@gmail.com (M.P. Arenhardt).

https://doi.org/10.1016/j.ctarc.2025.100997

Available online 9 September 2025
2468-2942/© 2025 The Authors. Published by Elsevier Ltd. This is an open access article under the CC BY-NC-ND license (http://creativecommons.org/licenses/by-nc-nd/4.0/).

therapy against HER2, has shown no significant activity in the CNS. In a phase II study, the combination of pertuzumab and high-dose trastuzumab achieved a CNS overall response rate (ORR) of 11 % [7]. In cases where local treatment is not indicated, the systemic therapy of choice has been capecitabine combined with tucatinib and trastuzumab [5,8], where tucatinib is available. This treatment is based on the HER2CLIMB trial, in which the 1-year CNS progression-free survival (PFS) rate was estimated at 40.2 % [9,10]. Another tucatinib-based combination has demonstrated significant activity in the CNS. In the phase III HER2CLIMB-02 trial, adding tucatinib to T-DM1 significantly improved PFS in patients with previously treated HER2-positive, extending it from 7.4 to 9.5 months (HR 0.76; $P = 0.0163$). However, it also failed to achieve a median PFS threshold of 12 months [11].

The systemic treatment of patients with brain metastases remains challenging, as many traditional cytotoxic chemotherapies and monoclonal antibodies fail to cross the blood-brain barrier (BBB) effectively. However, the emergence of antibody-drug conjugates (ADCs), particularly trastuzumab deruxtecan (T-DXd), which has demonstrated efficacy in the CNS, brings a sense of hope and optimism to the field of brain metastasis treatment. The potential of T-DXd in treating brain metastases is a promising development that warrants a reevaluation of current practices.

Methodology

This narrative review aims to synthesize and critically evaluate the current evidence on systemic treatments for HER2-positive brain metastases. A PubMed search using MeSH terms "breast cancer," “HER2," and "brain metastases" was conducted, and the search included clinical trials, meta-analyses, observational studies, and reviews published in the last ten years, yielding thirteen studies. Additionally, the ASCO guidelines for the treatment of HER2-positive breast cancer with CNS involvement and the ESMO guidelines for breast cancer management were also utilized. The NCCN guidelines were also consulted in the preparation of this article. A search was conducted on ClinicalTrials.gov to identify ongoing studies. This comprehensive review may provide a valuable resource for oncologists, researchers, and other healthcare professionals in breast cancer treatment.

The blood-brain barrier and the anti-HER therapy

The blood-brain barrier (BBB) is a semi-permeable barrier that surrounds the microvasculature of the central nervous system, controlling the entry and exit of molecules between the vascular compartment and the brain. This tight junction permits only the passive diffusion of lipid-soluble drugs with a molecular weight lower than 400–600 Da[12] . In addition, brain tumor microvessels further limit drug delivery by forming a physical barrier. Although this tumor barrier is more permeable than the BBB, it still significantly hinders the delivery of anticancer drugs to brain tumors [13].

Cytotoxic agents have historically limited central nervous system (CNS) activity [4], prompting the search for innovative strategies to address this significant weakness in the treatment of mBC. While the revolution in breast cancer treatment driven by HER2-targeted therapies marked a breakthrough, it initially achieved limited success in managing CNS involvement.

HER2-targeting drugs involve tyrosine kinase inhibitors (TKIs), monoclonal antibodies, and ADCs [14]. Monoclonal antibodies anti-HER2, including trastuzumab and pertuzumab, are generally considered to have limited ability to penetrate an intact blood-brain barrier [15]. Clinical data reflect that trastuzumab can not wholly cross the BBB to provide a preventive or therapeutic effect. A meta-analysis revealed that CNS metastases represented a higher proportion of first relapse sites in patients who received trastuzumab as adjuvant therapy [14] Data also shows that trastuzumab has a low concentration in the cerebrospinal fluid when administered intravenously. However, when the blood-brain barrier is disrupted by radiotherapy, trastuzumab concentrations in the central nervous system increase, and this effect is more pronounced when associated with leptomeningeal carcinomatosis [15].

Delivering trastuzumab directly into the cerebrospinal fluid (CSF) is a practical approach to bypass the limitations of the blood-leptomeningeal barrier. The data supporting its use comes from small, single-arm prospective studies and case series focused on patients with leptomeningeal carcinomatosis. In a phase II study, 19 patients received weekly administrations of 150 mg of intrathecal trastuzumab. After 8 weeks, 74 % of patients were free from neurological progression. The median LM-related PFS was 5.9 months, and the median OS was 7.9 months [16]. In another phase I/II study, 34 patients with leptomeningeal disease (LMD) received 80 mg of intrathecal trastuzumab twice weekly and achieved a median OS of 10.5 months [17]. Despite these data, a systematic review with meta-analysis showed that intrathecal administration of HER2-targeted therapy for patients with HER2+ breast cancer and LM does not offer additional benefits over oral and/or intravenous treatment regimens in terms of OS and CNS-specific PFS [18].

Central nervous system uptake of ADCs has been reported to be highly heterogeneous, and the differential efficacy and CNS penetration properties of various ADCs across distinct brain tumor types remain poorly understood. A complex interplay of pharmacological factors influences the effectiveness of ADCs. Molecules with a high drug-to-antibody rate (DAR) in heterogeneous formulations have demonstrated impaired accumulation in brain tumors compared to those with lower DARs, likely due to increased hydrophobicity and molecular weight [19]. However, these findings are based on studies utilizing monomethyl auristatin F as the payload, which may limit their generalizability. For instance, T-DXd exhibits substantial CNS activity despite its high DAR. The choice of payload is likely a critical factor influencing CNS penetration, in addition to the performance of the bystander effect. This effect might be significant given the strict regulation of drug influx by the blood-tumor barrier and the intratumoral heterogeneity in antigen expression and drug concentrations [19]. Besides drug-related factors, the partial disruption of the BBB at metastatic sites may contribute to the efficacy of ADCs in brain metastases despite their substantial molecular size [20]

Systemic treatment in the pre-antibody-drug conjugate era

Small-molecule HER2 kinase inhibitors may offer improved brain penetration. Lapatinib is a small dual TKI of HER1 and HER2 [21]. The single-arm phase II LANDSCAPE evaluated the combination of lapatinib and capecitabine ($L + C$) as first line treatment for patients with HER 2 positive mBC and BMs, trying to avoid whole brain radiotherapy (WBR). The rate of objective CNS response was 65.9 %. Grade 3 or 4 adverse events happened in 49 % of patients, with diarrhea being the most common [21]. With such high response rates, authors suggested that $L + C$ could be a viable alternative to immediate WBR.

CEREBEL is another trial approaching lapatinib, comparing the incidence of CNS metastases as first site of relapse in patients with HER2-positive metastatic breast cancer receiving lapatinib-capecitabine or trastuzumab-capecitabine. The trial was inconclusive for the primary endpoint, and no difference was detected between lapatinib-capecitabine and trastuzumab-capecitabine in the incidence of CNS metastases. A better outcome was observed with trastuzumab-capecitabine in the overall population. However, the efficacy of lapatinib-capecitabine may have been affected by previous exposure to a trastuzumab regimen and/or when treatment was administered as first- or second-line therapy in the metastatic setting.

Tucatinib, an oral TKI, is a highly selective small molecule targeting HER2. Its efficacy in brain metastases was evaluated in the phase III HER2CLIMB trial, using a regimen that included tucatinib, trastuzumab, and capecitabine. For patients with brain metastases treated with

tucatinib, the 1-year CNS PFS rate was estimated at 40.2 %, with a median CNS-PFS of 9.9 months. The 1-year OS rate was estimated at 70.1 %. Among the 75 patients with active BMs and measurable intracranial disease at baseline, the confirmed ORR-IC was 47.3 % [9]. Tucatinib treatment was, until then, the systemic anti-HER therapy with the highest activity in the CNS. Although the tucatinib-based regimen has been approved by the FDA and the European Medicines Agency (EMA), some countries, such as China and Brazil, have yet to grant regulatory approval as of December 2024.

Pyrotinib, another oral TKI targeting HER2, was incorporated into the anti-HER2 treatment arsenal following the phase III PHOEBE trial results [22]. In patients with brain metastases, the TKI was evaluated in a small study in combination with palbociclib and fulvestrant (Fulvestrant) in the HER2-positive, hormone receptor-positive population. Despite the limited sample size, the regimen demonstrated an intracranial response rate of approximately 59 %[23]. Pyrotinib has also been studied in combination with radiotherapy and capecitabine. In this multimodal approach, the 1-year CNS PFS rate was 74.9 %, and the median CNS PFS reached 18.0 months, with an acceptable incidence of radiation necrosis [24].

Systemic therapy with ADCs

The performance of other ADCs alone in BM was not encouraging before T-DxD. The EMILIA trial was a pivotal study demonstrating that the use of T-DM1 resulted in improved PFS and OS in the second-line treatment compared to lapatinib and capecitabine. The trial included 95 patients with stable and previously treated BMs. Among these patients, T-DM1 achieved a median PFS of 5.9 months, comparable to 5.7 months in the control arm (HR 1.00; $p = 1.000$), and a median OS of 26.8 months compared to 12.9 months (HR 0.38; $p = 0.008$) [25]. The KAMILLA trial, in turn, enrolled 398 patients with untreated, asymptomatic, or controlled BM to receive T-DM1. In this cohort, the ORR was 21.4 %. Among patients without BM, 9.6 % developed CNS disease during ADC treatment [26]. Furthermore, a strategy combining the ADC TDM1 with TKI was evaluated in the HER2CLIMB-02 trial. Patients with HER2-positive mBC who had previously received taxane plus trastuzumab were randomized to receive tucatinib plus TDM-1 or tucatinib plus placebo. Nearly half of the population had BM without indications for urgent local therapy. The median PFS was 9.5 months (95 % CI, 7.4–10.9) in the tucatinib+TDM1 arm, compared to 7.4 months (95 % CI, 5.6–8.1) in the control arm [11].

The distinction between stable and active brain metastases has become more clearly defined in modern clinical trials. In particular, studies involving T-DXd have adopted the following criteria: active brain metastases are considered those that are symptomatic, progressing, or requiring corticosteroids; stable brain metastases are those previously treated (with surgery or radiotherapy), with no evidence of progression for ≥4 weeks [27]. T-DXd was first approved based on the phase II DESTINY-Breast01 trial results, in which patients previously treated with trastuzumab emtansine achieved a median PFS of 16.4 months [28]. The next significant milestone was the DESTINY-Breast03 trial, which established T-DXd as the standard second-line treatment for HER2-positive metastatic breast cancer [29]. Only patients with treated BMs were included in both trials, leaving the drug's efficacy in the central nervous system an unresolved question.

Two small trials evaluated T-DXd in patients with untreated BMs. In the phase II DEBBRA trial, patients were categorized into one of five cohorts to receive T-DXd. Cohort 1 included 8 individuals with HER-2 positive mBC with stable BMs following local treatment with radiotherapy and/or surgery; cohort 2 comprised 4 patients with either HER2-positive or HER2-low ABC and asymptomatic, untreated BMs. Cohort 3 encompassed those with HER2-positive tumors with progressing BMs despite prior local treatment (9 patients). Cohort 4 included patients with HER2-low mBC and progressing BMs after local therapy. Finally, Cohort 5 consisted of patients with either HER2-positive or HER2-low ABC and untreated leptomeningeal carcinomatosis and enrolled 7 patients. Overall, the ORR-IC in patients with active BMs was 46.2 %. ORR-IC was 50.0 % in cohort 2 and 44.4 % in cohort 3 [30]. Cohort 5 enrolled seven patients with LMD. In a follow-up of 12 months, two patients were alive and remained on treatment. Besides that, it is essential to highlight that four out of five patients presented extracranial progression at the time of failure, and no one had clinical worsening of leptomeningeal symptoms. The median OS was 13.3 months [31]. The second, TUXEDO-1 trial, was a single-arm phase II trial in patients with progressing or untreated CNS disease. The inclusion criteria did not require immediate local therapy, although 40 % of patients had neurological symptoms at baseline. They achieved an IC—ORR of 73.3 %, with 13.3 % of patients achieving complete remission. The median PFS was 14 months [20].

Table 1
Studies with trastuzumab deruxtecan in HER2-positive breast cancer with brain metastases.

	Brain Metastases	N	IC—ORR	PFS (months)	OS
DB-01,02 and 03	Overall			16.4	
	Treated and stable	104	45.2 %		
	Untreated and active	44	45.5 %		
DEBBRA					
Cohort 1	Treated and stable	8	80 %		
Cohort 2	Untreated and asymptomatic	4	50 %		
Cohort 3	Progressing BM	9	44.4 %		
Cohort 4	Progressing BM HER2 low	4	33.4 %		
Cohort 5	LMD	7		8.9	13.3
TUXEDO	Progressing or active	15	73.3 %	14	
DB-12	Overall			17.3	12-m OS rate 90.3 %
	Active	106	62.3 %		
	Untreated	39	50 %		
	Treated and progressing	67	82.6 %		

A pooled analysis of T-DXd in patients with brain metastases from the DESTINY-Breast-01, −02, and −03 trials began to address the question more effectively [32]. Among 148 patients with BMs at baseline, 70.3 % had been treated, and 29.7 % had untreated BMs. In patients with untreated brain metastasis, the IC—ORR was 45.5 %, and in patients with treated BM, the IC—ORR was 45.2 % [32]. In addition, a meta-analysis of T-DXd in HER2-positive breast cancer with BM combined data from six clinical trials conducted before the publication of DB-12. The results support the use of the ADC in both stable and active BM, with the following outcomes: the ORR was 68 % (95 % CI: 57 % to 77 %) in the subgroup of patients with stable BM and 60 % (95 % CI: 48 % to 72 %) in patients with active BM [33]

More recently, data from the DESTINY-Breast12 trial were published. This is the first phase III/IV trial to enroll patients with active brain metastases. The cohort of patients with CNS disease was composed of 236 patients. Among them, 39 had untreated brain metastases, and 67 had previously treated brain metastases that were progressing at study entry, with no clinical indication for immediate retreatment with local therapy [27]. The patients had been previously treated, 50 % with one prior line of systemic treatment, and 40 % with two; furthermore, 60 % had received radiotherapy. The median PFS for the BM cohort was 17.3 months; the 12-month CNS PFS was 58.9 %. Within the active BM subgroup, PFS at 12 months was 47.0 % in patients with untreated BM and 66.7 % in those with previously treated or progressing BM. The CNS ORR was 62.3 % with active BM, 82.6 % in untreated BM, and 50 % in previously treated and progressing BM [27]. Although OS data are not yet mature, the overall 12-month OS rate was 90.3 %. In the subgroup of

Table 2
Ongoing phase II trials of ADCs in HER2-positive breast cancer with active brain metastasis.

NCT identifier	Title	Phase	Drug	Subtype of BC	BM	Primary Endpoint
NCT04538742	Destiny-Breast07	Ib/II	TDx-D x TDx-D plus pertuzumab	HER2 positive	Stable and active BM	Part 1: Safety. Part 2: ORR and PFS?
NCT06048718	Tuxedo-4	II	TDx-D	HER2 low	Stable, active BM and LMD	ORR
NCT04539938	HER-CLIMB4	II	Tucatinib plus TDx-D	HER2 positive	Stable and active BM	ORR
NCT05865990	TUXEDO-3	II	Patritumab deruxtecan (HER3-DXd)	HER2-positive BC and NSCLC	Active BM and LMD	IC—ORR
NCT06475443		II	Pyrotinib Plus Capecitabine	HER2-positive	Active BMs that have failed ADCs	CNS-ORR

* BC: breast cancer.
*LMD: leptomeningeal disease.
* NSCLC: non–small cell lung cancer.

patients with stable BM, the 12-month OS rate was 93.2 %, whereas in the subset with active BM, it was 86.1 %[27]. The median total treatment duration in the BM cohort was 11.5 months. These results demonstrate that T-DXd exhibited substantial and durable overall and intracranial clinical activity in a cohort of patients with stable and active brain metastases. In a real-world cohort of patients with brain metastases, the intracranial objective response rate was 58 %, and the PFS reached 11.8 months. These findings support the high activity of the drug within the CNS [34].The main trials of TDx-D are described in Table 1.

Adverse events profile

The concern for quality of life has become relevant in treatment selection in metastatic disease settings. In the HER2-CLIMB trial, diarrhea was the most common adverse event associated with tucatinib-based treatment, which occurred in 80 % of patients at any grade. Additionally, palmar-plantar erythrodysesthesia syndrome was a concern, with 13 % of patients experiencing this event at grade 3 [10]. In the Destiny-Breast12, the most common adverse event was nausea, and pneumonitis occurred in 16 % of patients with BM. No grade 4 or higher events occurred [27]. Pneumonitis or interstitial lung disease (ILD) is the primary adverse event of special interest associated with trastuzumab deruxtecan. In the DESTINY-Breast03 study, pneumonitis/ILD was reported in 10.7 % of patients, with 7 % experiencing Grade 2 events. Notably, pneumonitis-related deaths occurred in the DESTINY-Breast01 trial. To enable early detection and management, patients and healthcare professionals should be adequately educated about the signs and symptoms of pneumonitis. A baseline scan is recommended, followed by repeat scans every 6–12 weeks [29].

Leptomeningeal disease

LMD is defined as the spread of tumor cells within the leptomeninges and the subarachnoid space and is typically linked to a rapid deterioration in neurological function, a decline in quality of life, and a reduced life expectancy [35,36]. In a cohort of 82 patients with advanced HER2-positive breast cancer and LMD, the OS was 8.3 months, and the presence of neurological symptoms was associated with poorer survival [35]. Despite the poor prognosis, OS is generally longer in patients with HER2-positive disease compared to other subtypes with leptomeningeal involvement [37]. The current guidelines advocate for intrathecal therapy, mainly when tumor cells are detected in the cerebrospinal fluid (CSF) or in cases of linear leptomeningeal metastasis. Although current evidence is limited to small phase I and II studies, trastuzumab has been employed as an intrathecal therapy. Reported outcomes demonstrate a median overall survival ranging from 7.9 to 10.5 months [16,17]. Focal RT is the preferred treatment for nodular disease and symptomatic brain or spinal cord lesions. Whole-brain radiation therapy (WBRT) is not considered the standard of care due to its lack of demonstrated survival benefit and its toxicity. WBRT is typically reserved for patients with widespread nodular or symptomatic LMD or those with concurrent brain metastases and is used as a purely palliative measure [36].

The combination therapy of tucatinib, capecitabine, and trastuzumab achieved a median OS of 11.9 months and a median time to CNS progression of 6.9 months in a phase II trial that included patients with LMD [38]. The Destiny-Breast 12 did not enroll patients with meningeal carcinomatosis [20]. As mentioned, the small Debbrah trial enrolled these patients, achieving a median PFS of 8.9 months and a median OS of 13.3 months [31]. In addition to that data, the ROSET-BM trial addressed these patients, including 19 patients with LMD to be treated with T-DXD. The 12-month PFS and OS rates were 60.7 % and 87.1 %, respectively. Nine patients had associated BM; the IC—ORR was 77.8 %, highlighting a potential treatment option for this high-risk patient population [39].

Lessons from unsuccessful strategies

A phase II trial investigated palbociclib in combination with trastuzumab in patients with HER2-positive BM. Twelve patients were enrolled, but no objective responses were observed. An interesting aspect of this study was the use of circulating tumor DNA (ctDNA). At baseline, the median variant allele frequency (VAF) for the dominant alteration was 0.18 % (interquartile range [IQR], 0.12 %–0.47 %). The median number of somatic alterations detected at baseline was 1, with *TP53* being the most frequently identified alteration ($n = 4$). Notably, only 8 % of the patients had progressing systemic disease, which could explain the low VAF observed. This suggests that in patients where brain metastases were the sole site of new or progressive disease, ctDNA exhibited a low variant allele fraction and fewer detectable alterations [40].

Perspectives of ADCs in HER2-positive brain metastases

The ongoing DESTINY-Breast07 is assessing T-DXd with or without pertuzumab as the first line of treatment for HER-2 metastatic breast cancer. T-DXd demonstrated an ORR of 82.7 %, while T-DXd plus pertuzumab achieved 88 % of ORR. Patients with stable or active BM could be included, but the efficacy results in these cohorts have yet to be available (NCT04538742) [41].

The TUXEDO-4 trial is a phase II trial to evaluate the safety and efficacy of T-DXd in HER2-low breast cancer with newly diagnosed or progressing brain metastases with or without untreated leptomeningeal disease (NCT06048718).

HER2CLIMB-04 (NCT04539938) is a phase 2 trial evaluating the safety and antitumor activity of tucatinib plus T-DXd in patients with HER2-positive metastatic breast cancer and active or stable BMs. The inclusion criteria specify that patients must have received two or more prior HER2-based regimens in the metastatic setting. The study is active but no longer recruiting participants.

TUXEDO-3 is a phase II basket trial in which patients with active BM and leptomeningeal disease (LMD) from breast cancer or non-small cell lung cancer (NSCLC) will receive patritumab deruxtecan (HER3-DXd) as treatment (NCT05865990).

Table 3
Results of the cohorts with BM of phase III trials HER2 CLIMB and DESTINY-BREAST 12.

	HER2 CLIMB Cohort with BM	Destiny-Breast 12 Cohort with BM
Intervention	Tucatinib, trastuzumab, capecitabine.	Trastuzumab-deruxtecan.
Population	Previously treated with trastuzumab, pertuzumab, and T-DM1	≤ 2 lines of treatment: 98 % received trastuzumab and 40 % T-DM1
Brain Metastasis in the Intervention Cohort	*N*= 198	*N*= 263
Stable	*N*= 80	*N*= 157
Treated and progressing	*N*= 74	*N*= 67
Untreated	*N*= 44	*N*= 39
Leptomeningeal disease	Excluded	Excluded
Prior RT for BM	70 %	60 %
IC—ORR Active BM	47.3 %	62.3 %
1-year CNS PFS	40.2 %	58.9 %
1-year OS	70 %	90.3 %

The sequencing of treatment after ADCs remains an unresolved question. The NCT06475443 study is a phase II clinical trial evaluating the combination of pyrotinib and capecitabine in patients with HER2-positive cancer. The trial focuses on active BM that has progressed after treatment with ADCs. The primary endpoint is the CNS-ORR.

Another interesting prospective trial is assessing the use of MRI in screening patients with HER2-positive and triple-negative breast cancer in stages II and III. Understanding the incidence of asymptomatic BMs and the impact of early diagnosis is crucial for improving screening tools and therapeutic strategies (NCT06247449).

The phase II trials enrolling patients with active BM are summarized in Table 2.

Discussion

T-DXd has been proven effective in patients with active BM. This ADC demonstrated higher IC—ORR and PFS than tucatinib in the HER2CLIMB study (Table 3). These results show that T-DXd is now the preferred second-line therapy for patients with or without brain metastases. Regarding local treatment, the ASCO guidelines recommend treating selected patients with asymptomatic BM with systemic therapy. This recommendation is further reinforced by new efficacy data in patients with active brain metastases, indicating that patients chosen may forgo local treatment and benefit solely from systemic therapy. For instance, the reduced use of WBRT may result in fewer events related to cognitive decline, which could be a key factor in maintaining quality of life.

Although the results of DESTINY-Breast12 are very encouraging, it is essential to highlight that having brain metastases with an urgent need for local therapy was an exclusion criterion [27]. This potential selection bias, by excluding patients with worse prognosis, could lead to better results with T-DXd in this setting.

Besides the indication for local therapy, attention should be given to corticosteroids. In the DEBBRA trial, corticosteroids were permitted if a stable dose had been maintained for at least 4 weeks, while in the

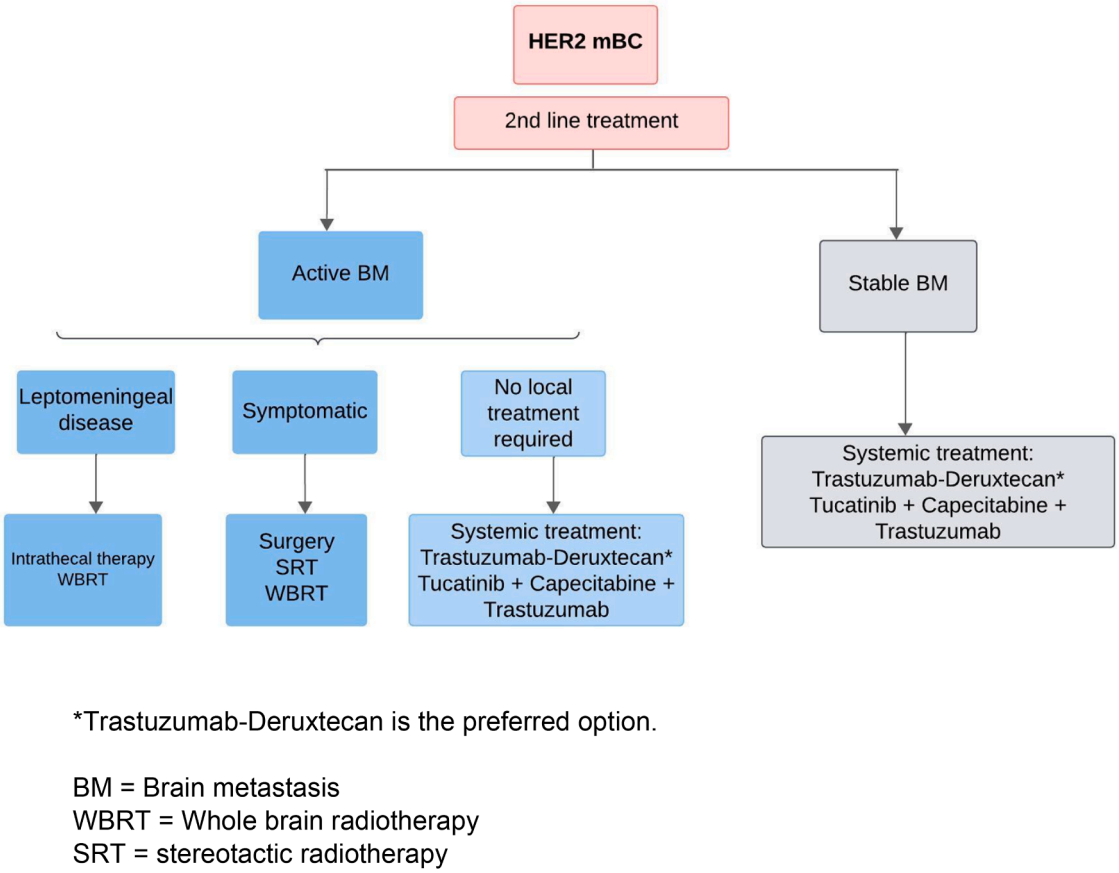

Fig. 1. Suggested algorithm for the primary treatment of HER2 mBC with BM.
*Trastuzumab-Deruxtecan is the preferred option.
BM = Brain metastasis
WBRT = Whole brain radiotherapy
SRT = stereotactic radiotherapy.

TUXXEDO-1 trial, they were allowed at doses lower than 4 mg per day. TUXXEDO-1 even had impressive results (with a best overall intracranial response rate of 73.3 %), but with only fifteen patients. The efficacy results of T-DXd likely reflect outcomes in patients without severe symptoms or life-threatening conditions, and local treatment may remain critical for this subgroup of patients with symptomatic disease, as the algorithm suggested by the authors in Fig. 1.

Although scientific knowledge has advanced, this remains a group of patients with a prognosis that could be improved, and several questions in this field remain unanswered. The role of radiotherapy in patients with BM in the ADCs era should be re-evaluated, particularly for patients with asymptomatic BM who have access to systemic therapies with CNS activity. . It is important to note that the concomitant use of ADCs and radiotherapy may increase the risk of symptomatic radionecrosis (SRN), with studies reporting a two-year cumulative incidence of SRN as high as 27 % [42].

Another point that may warrant reconsideration is the use of imaging exams as a screening tool for asymptomatic patients with locally advanced HER2-positive breast cancer, given the availability of effective treatments for CNS disease. Additionally, incorporating ADCs is expected to lead to improved responses in BM, likely enhancing both survival and quality of life for patients. However, there remains uncertainty regarding the optimal sequence of treatments following ADC use. The optimal approach following the use of ADCs is an unresolved question, underscoring the need for further clinical studies to determine the best strategies for managing patients post-therapy.

Conclusion

Trastuzumab deruxtecan has proven effective in HER2-positive BM, and this data is likely to change the treatment algorithm for CNS disease. Local therapy remains essential, particularly for patients with symptomatic or high-volume disease, and the management of these patients should be discussed within a multidisciplinary team. Currently, there is no available data on the efficacy of TDx-D in HER2-low patients with active BM, and despite the significant improvement in outcomes overall, patients with LMD remain a particularly challenging group with a poorer prognosis.

CRediT authorship contribution statement

Martina Parenza Arenhardt: Writing – review & editing, Writing – original draft, Methodology. **Carolina Martins Vieira:** Writing – review & editing, Writing – original draft, Methodology. **Angélica Nogueira-Rodrigues:** Writing – review & editing, Conceptualization.

Declaration of competing interest

The authors declare that they have no known competing financial interests or personal relationships that could have appeared to influence the work reported in this paper.

References

[1] A.C. Wolff, M.R. Somerfield, M. Dowsett, M.E.H. Hammond, D.F. Hayes, L. M. McShane, et al., Human epidermal growth factor receptor 2 testing in breast cancer: aSCO–College of American Pathologists guideline update, J. Clin. Oncol. [Internet] (2023). Aug 1 [cited 2024 Oct 24]; Available from: https://ascopubs.org/doi/10.1200/JCO.22.02864.

[2] S.M. Swain, D. Miles, S.B. Kim, Y.H. Im, S.A. Im, V. Semiglazov, et al., Pertuzumab, trastuzumab, and docetaxel for HER2-positive metastatic breast cancer (CLEOPATRA): end-of-study results from a double-blind, randomised, placebo-controlled, phase 3 study, Lancet Oncol. 21 (4) (2020 Apr) 519–530.

[3] A.S. Raghavendra, N.K. Ibrahim, Breast cancer brain Metastasis: a comprehensive review, JCO Oncol. Pract. [Internet] (2024). Oct [cited 2024 Oct 24]; Available from: https://ascopubs.org/doi/10.1200/OP.23.00794.

[4] E. Le Rhun, M. Guckenberger, M. Smits, R. Dummer, T. Bachelot, F. Sahm, et al., EANO–ESMO clinical practice guidelines for diagnosis, treatment and follow-up of patients with brain metastasis from solid tumours, Ann. Oncol. 32 (11) (2021 Nov) 1332–1347.

[5] A. Gennari, F. André, C.H. Barrios, J. Cortés, E. De Azambuja, A. DeMichele, et al., ESMO clinical practice guideline for the diagnosis, staging, and treatment of patients with metastatic breast cancer, Ann. Oncol. 32 (12) (2021 Dec) 1475–1495.

[6] N. Ramakrishna, C.K. Anders, N.U. Lin, A. Morikawa, S. Temin, S. Chandarlapaty, et al., Management of advanced Human epidermal growth factor receptor 2–Positive breast cancer and brain metastases: ASCO guideline update, J. Clin. Oncol. [Internet] (2022). Aug 10 [cited 2024 Oct 24]; Available from: https://ascopubs.org/doi/10.1200/JCO.22.00520.

[7] N.U. Lin, M. Pegram, S. Sahebjam, N. Ibrahim, A. Fung, A. Cheng, et al., Pertuzumab plus high-dose trastuzumab in patients with progressive brain metastases and HER2-positive metastatic breast cancer: primary analysis of a phase II study, J. Clin. Oncol. 39 (24) (2021) 2667–2675. Aug 20.

[8] HER2-positive breast cancer, ESMO [Internet] [cited 2024 Dec 5]. Available from: https://www.esmo.org/living-guidelines/esmo-metastatic-breast-cancer-living-guideline/her2-positive-breast-cancer/her2-positive-breast-cancer/first-and-second-lines.

[9] N.U. Lin, R.K. Murthy, V. Abramson, C. Anders, T. Bachelot, P.L. Bedard, et al., Tucatinib vs Placebo, both in combination with Trastuzumab and Capecitabine, for previously treated ERBB2 (HER2)-positive metastatic breast cancer in patients with brain metastases: updated exploratory analysis of the HER2CLIMB randomized clinical trial, JAMA Oncol. 9 (2) (2023 Feb) 197.

[10] R.K. Murthy, S. Loi, A. Okines, E. Paplomata, E. Hamilton, S.A. Hurvitz, et al., Tucatinib, Trastuzumab, and Capecitabine for HER2-positive metastatic breast cancer, N. Engl. J. Med. 382 (7) (2020 Feb 13) 597–609.

[11] S. Hurvitz, S. Loi, J. O'Shaughnessy, A. Okines, S. Tolaney, J.H. Sohn, et al., Abstract GS01-10: HER2CLIMB-02: randomized, double-blind phase 3 trial of Tucatinib and Trastuzumab Emtansine for previously treated HER2-positive metastatic breast cancer, Cancer Res. 84 (2024 May 2) (9_Supplement):GS01-10.

[12] D. Wu, Q. Chen, X. Chen, F. Han, Z. Chen, Y. Wang, The blood–brain barrier: structure, regulation and drug delivery, Signal Transduct. Target Ther. 8 (1) (2023 May 25) 1–27.

[13] R.K. Upadhyay, Drug delivery systems, CNS protection, and the blood brain barrier, BioMed Res. Int. 2014 (1) (2014) 869269.

[14] Q. Chen, J. Xiong, Y. Ma, J. Wei, C. Liu, Y. Zhao, Systemic treatments for breast cancer brain metastasis, Front. Oncol. [Internet] 12 (2023). Jan 6 [cited 2024 Nov 4]Available from: https://www.frontiersin.org/journals/oncology/articles/10.3389/fonc.2022.1086821/full.

[15] H.J. Stemmler, M. Schmitt, A. Willems, H. Bernhard, N. Harbeck, V. Heinemann, Ratio of trastuzumab levels in serum and cerebrospinal fluid is altered in HER2-positive breast cancer patients with brain metastases and impairment of blood–brain barrier, Anticancer Drugs 18 (1) (2007 Jan) 23–28.

[16] F. Oberkampf, M. Gutierrez, O. Trabelsi Grati, É. Le Rhun, O. Trédan, I. Turbiez, et al., Phase II study of intrathecal administration of trastuzumab in patients with HER2-positive breast cancer with leptomeningeal metastasis, Neuro-Oncol. 25 (2) (2023 Feb 14) 365–374.

[17] P.U. Kumthekar, M.J. Avram, A.B. Lassman, N.U. Lin, E. Lee, S.A. Grimm, et al., A phase I/II study of intrathecal trastuzumab in human epidermal growth factor receptor 2-positive (HER2-positive) cancer with leptomeningeal metastases: safety, efficacy, and cerebrospinal fluid pharmacokinetics, Neuro-Oncol. 25 (3) (2023 Mar 14) 557–565.

[18] A.M. Lazaratos, S.M. Maritan, A. Quaiattini, A. Darlix, I. Ratosa, E. Ferraro, et al., Intrathecal trastuzumab versus alternate routes of delivery for HER2-targeted therapies in patients with HER2+ breast cancer leptomeningeal metastases, Breast 69 (2023 Jun) 451–468.

[19] M.J. Mair, R. Bartsch, E. Le Rhun, A.S. Berghoff, P.K. Brastianos, J. Cortes, et al., Understanding the activity of antibody–drug conjugates in primary and secondary brain tumours, Nat. Rev. Clin. Oncol. 20 (6) (2023 Jun) 372–389.

[20] Trastuzumab deruxtecan in HER2-positive breast cancer with brain metastases: a single-arm, phase 2 trial, Nat. Med. [Internet] (2024) citedOct 24]. Available from: https://www.nature.com/articles/s41591-022-01935-8.

[21] T. Bachelot, G. Romieu, M. Campone, V. Diéras, C. Cropet, F. Dalenc, et al., Lapatinib plus capecitabine in patients with previously untreated brain metastases from HER2-positive metastatic breast cancer (LANDSCAPE): a single-group phase 2 study, Lancet Oncol. 14 (1) (2013 Jan 1) 64–71.

[22] B. Xu, M. Yan, F. Ma, X. Hu, J. Feng, Q. Ouyang, et al., Pyrotinib plus capecitabine versus lapatinib plus capecitabine for the treatment of HER2-positive metastatic breast cancer (PHOEBE): a multicentre, open-label, randomised, controlled, phase 3 trial, Lancet Oncol. 22 (3) (2021 Mar 1) 351–360.

[23] Pyrotinib and trastuzumab plus palbociclib and fulvestrant in HR+/HER2+ breast cancer patients with brain metastasis, NPJ Breast Cancer [Internet] (2025) citedMay 21]. Available from: https://www.nature.com/articles/s41523-024-00646-2.

[24] Z. Yang, J. Meng, X. Mei, M. Mo, Q. Xiao, X. Han, et al., Brain radiotherapy with Pyrotinib and Capecitabine in patients with ERBB2-positive advanced breast cancer and Brain metastases: a nonrandomized phase 2 trial, JAMA Oncol. 10 (3) (2024 Mar 1) 335–341.

[25] I.E. Krop, N.U. Lin, K. Blackwell, E. Guardino, J. Huober, M. Lu, et al., Trastuzumab emtansine (T-DM1) versus lapatinib plus capecitabine in patients with HER2-positive metastatic breast cancer and central nervous system metastases: a retrospective, exploratory analysis in EMILIA†, Ann. Oncol. 26 (1) (2015 Jan 1) 113–119.

[26] F. Montemurro, S. Delaloge, C.H. Barrios, R. Wuerstlein, A. Anton, E. Brain, et al., Trastuzumab emtansine (T-DM1) in patients with HER2-positive metastatic breast cancer and brain metastases: exploratory final analysis of cohort 1 from KAMILLA,

a single-arm phase IIIb clinical trial☆, Ann. Oncol. 31 (10) (2020 Oct 1) 1350–1358.
[27] N. Harbeck, E. Ciruelos, G. Jerusalem, V. Müller, N. Niikura, G. Viale, et al., Trastuzumab deruxtecan in HER2-positive advanced breast cancer with or without brain metastases: a phase 3b/4 trial, Nat. Med. (2024 Sep 13) 1–10.
[28] S. Modi, C. Saura, T. Yamashita, Y.H. Park, S.B. Kim, K. Tamura, et al., Trastuzumab Deruxtecan in previously treated HER2-positive breast cancer, N. Engl. J. Med. 382 (7) (2020 Feb 13) 610–621.
[29] J. Cortés, S.B. Kim, W.P. Chung, S.A. Im, Y.H. Park, R. Hegg, et al., Trastuzumab Deruxtecan versus Trastuzumab Emtansine for breast cancer, N. Engl. J. Med. 386 (12) (2022 Mar 24) 1143–1154.
[30] Trastuzumab deruxtecan in patients with central nervous system involvement from HER2-positive breast cancer: the DEBBRAH trial | Neuro-Oncology | Oxford Academic [Internet] [cited 2024 Oct 24]. Available from: https://academic.oup.com/neuro-oncology/article/25/1/157/6593857?login=false.
[31] M. Vaz Batista, J.M. Pérez-García, L. Garrigós, J.Á. García-Sáenz, P. Cortez, F. Racca, et al., The DEBBRAH trial: trastuzumab deruxtecan in HER2-positive and HER2-low breast cancer patients with leptomeningeal carcinomatosis, Med [Internet] (2024 Sep 11) [cited 2024 Nov 22]; Available from: https://www.sciencedirect.com/science/article/pii/S266663402400312X.
[32] S.A. Hurvitz, S. Modi, W. Li, Y.H. Park, W. Chung, S.B. Kim, et al., 377O A pooled analysis of trastuzumab deruxtecan (T-DXd) in patients (pts) with HER2-positive (HER2+) metastatic breast cancer (mBC) with brain metastases (BMs) from DESTINY-Breast (DB) -01, -02, and -03, Ann Oncol 34 (2023 Oct 1) S335–S336.
[33] I. Michelon, M. Vilbert, A.D. Marinho, C.E.R. Castro, M.I. Dacoregio, C. Stecca, et al., Trastuzumab deruxtecan in human epidermal growth factor receptor 2-positive breast cancer brain metastases: a systematic review and meta-analysis, ESMO Open 9 (2) (2024 Feb) 102233.
[34] A. Fabi, A. Rossi, R. Caputo, S. Pisegna, S. Scagnoli, F. Pantano, et al., Real life outcome analysis of breast cancer brain metastases treated with Trastuzumab Deruxtecan, NPJ Precis. Oncol. 9 (1) (2025 Jan 22) 1–8.
[35] I. Ratosa, N. Dobnikar, M. Bottosso, M.V. Dieci, W. Jacot, S. Pouderoux, et al., Leptomeningeal metastases in patients with human epidermal growth factor receptor 2 positive breast cancer: real-world data from a multicentric European cohort, Int. J. Cancer 151 (8) (2022) 1355–1366.
[36] E. Le Rhun, M. Weller, M. van den Bent, D. Brandsma, J. Furtner, R. Rudà, et al., Leptomeningeal metastasis from solid tumours: EANO–ESMO Clinical Practice Guideline for diagnosis, treatment and follow-up☆, ESMO Open 8 (5) (2023 Oct 1) 101624.
[37] R. Bartsch, K.J. Jerzak, L. Larrouquere, V. Müller, E. Le Rhun, Pharmacotherapy for leptomeningeal disease in breast cancer, Cancer Treat. Rev. 122 (2024 Jan) 102653.
[38] R.K. Murthy, B. O'Brien, D.A. Berry, A. Singareeka-Raghavendra, M.G. Monroe, J. Johnson, et al., Abstract PD4-02: safety and efficacy of a tucatinib-trastuzumab-capecitabine regimen for treatment of leptomeningeal metastasis (LM) in HER2-positive breast cancer: results from TBCRC049, a phase 2 non-randomized study, Cancer Res. 82 (2022 Feb 15) (4_Supplement):PD4-02.
[39] N. Niikura, T. Yamanaka, H. Nomura, K. Shiraishi, H. Kusama, M. Yamamoto, et al., Treatment with trastuzumab deruxtecan in patients with HER2-positive breast cancer and brain metastases and/or leptomeningeal disease (ROSET-BM), NPJ Breast Cancer 9 (1) (2023 Oct 11) 82.
[40] A.N. Shah, C.A. Santa-Maria, D. Mukhija, N. Shah, A.K. Kang, P. Kumthekar, et al., A phase II single-arm study of Palbociclib in patients with HER2-positive breast cancer with brain metastases and analysis of ctDNA in patients with active brain metastases, Clin. Breast Cancer 23 (3) (2023 Apr) 324–329.
[41] F. Andre, E.P. Hamilton, S. Loi, C.K. Anders, P. Schmid, D. Stroyakovskiy, et al., DESTINY-Breast07: dose-expansion interim analysis of T-DXd monotherapy and T-DXd + pertuzumab in patients with previously untreated HER2+ mBC, J. Clin. Oncol. 42 (16_suppl) (2024 Jun) 1009, 1009.
[42] K. Debbi, M.A. Benderra, J. Medioni, C. Durdux, N.H. To, C. Boukhobza, et al., Safety and efficacy of combined trastuzumab-deruxtecan and concurrent radiation therapy in breast cancer. The TENDANCE multicentric French study, Breast 80 (2025) 104421, https://doi.org/10.1016/j.breast.2025.104421. AprEpub 2025 Feb 13. PMID: 39983437; PMCID: PMC11893322.